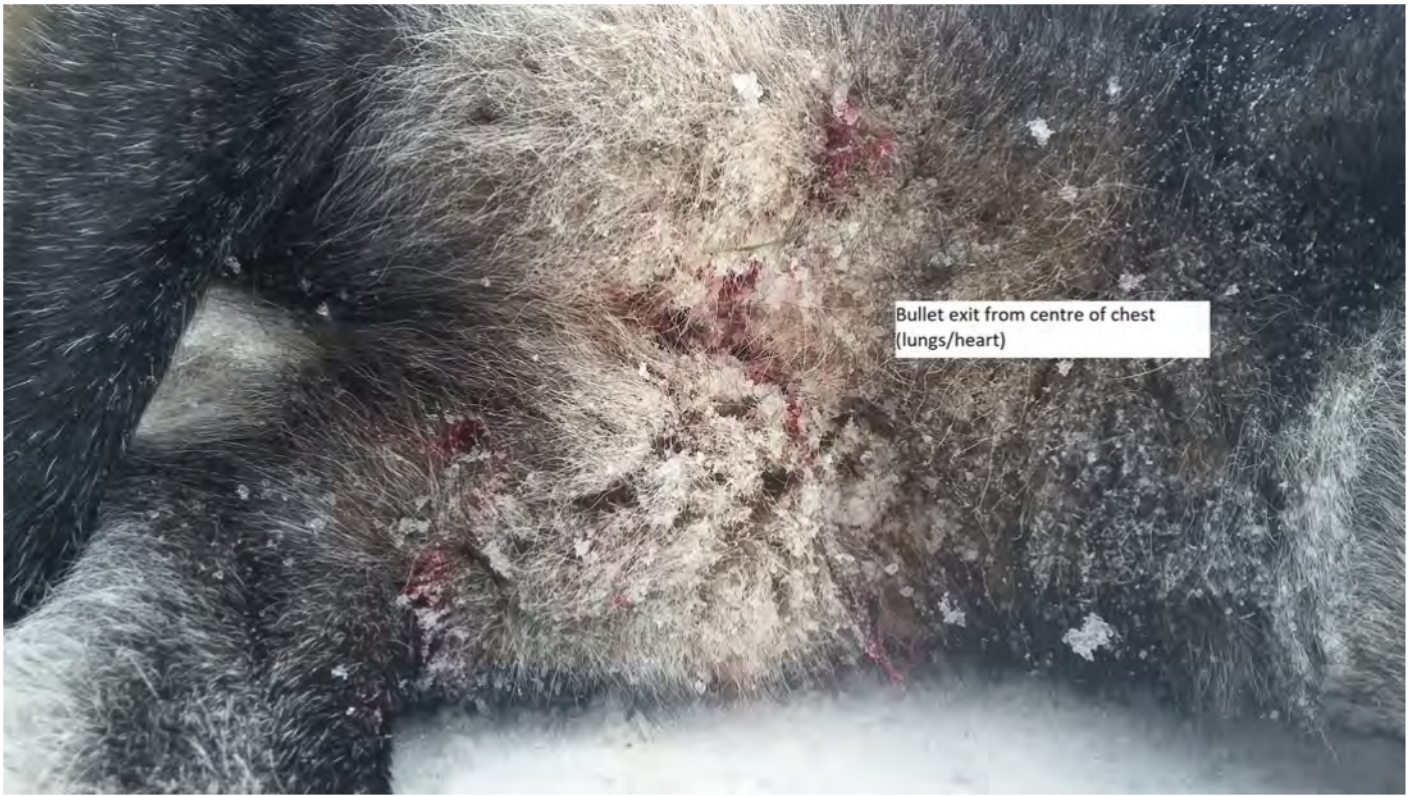




Wolf as it lays following instant
dispatch







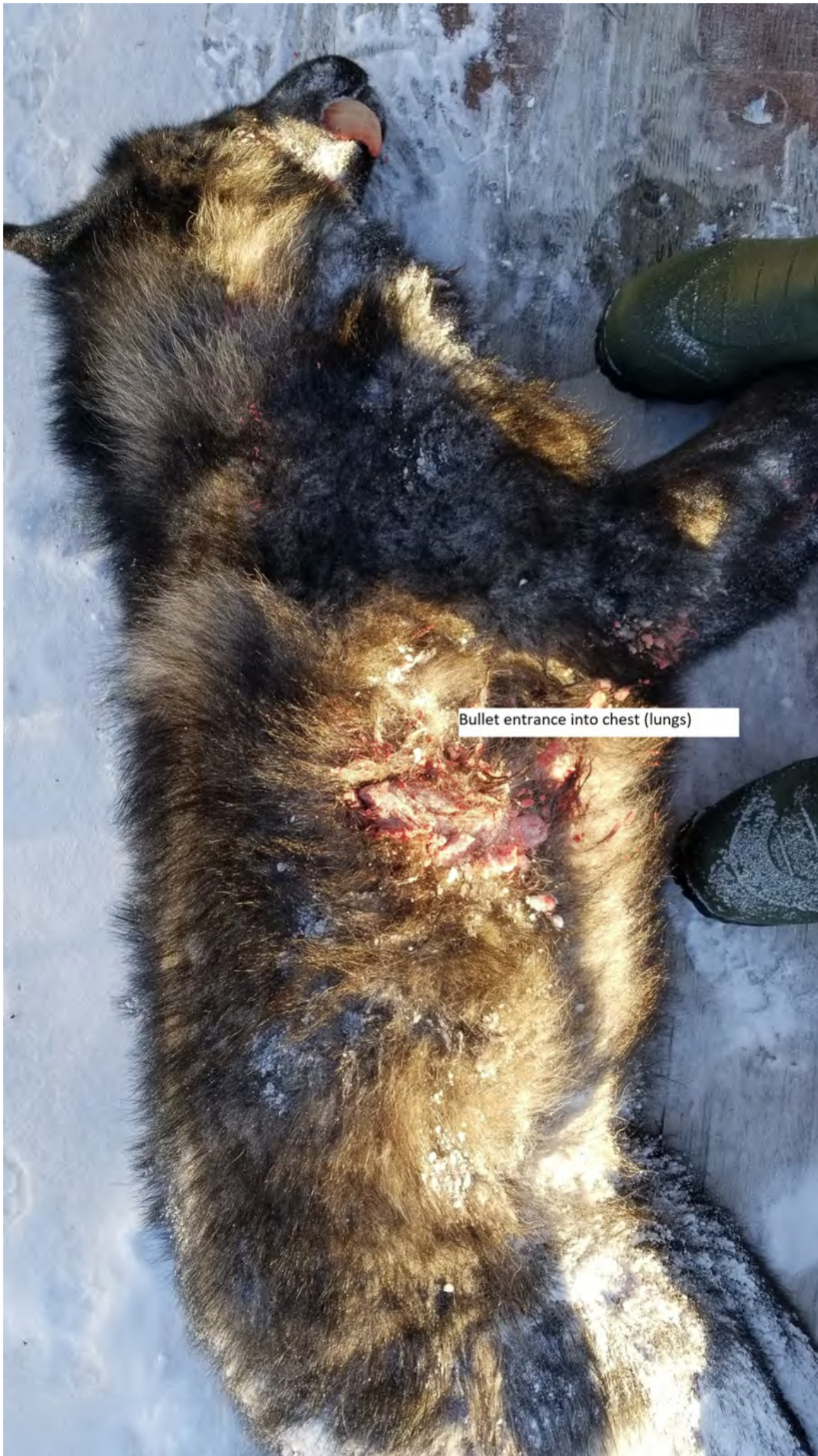

Bullet entrance downward into chest
cavity (lungs/heart)







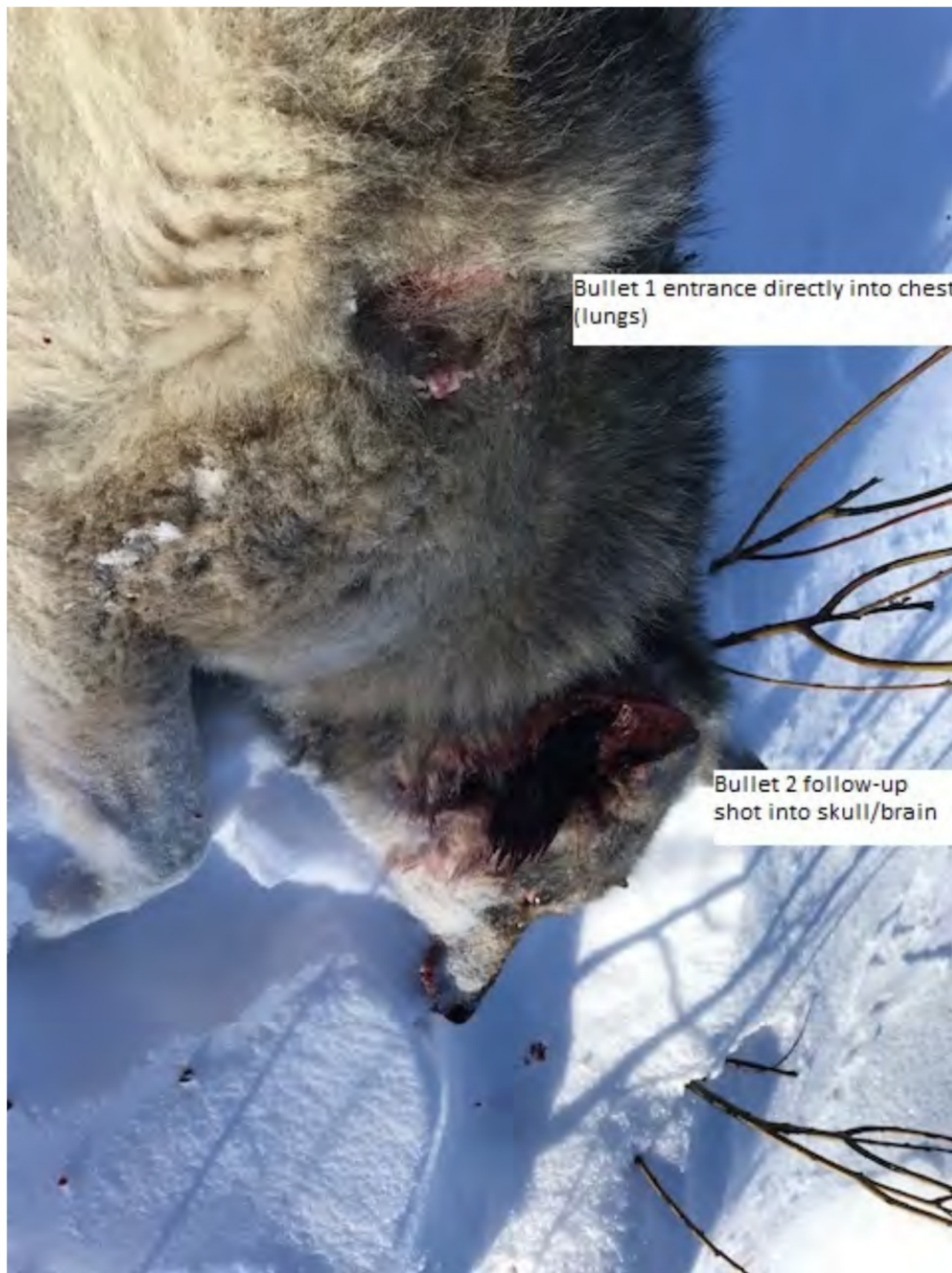








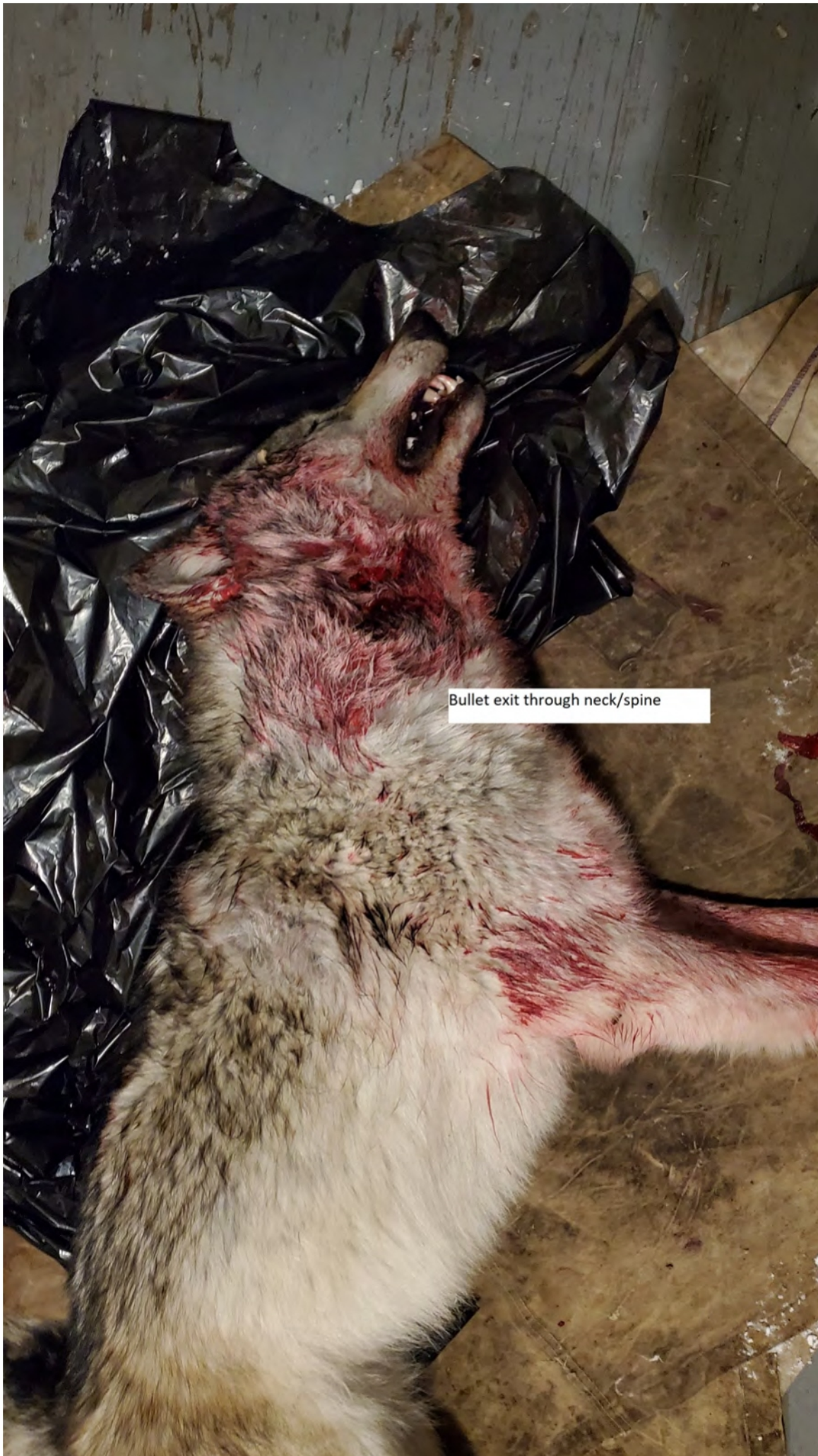


Bullet 1 entrance directly into chest (lungs)

Bullet 2 follow-up shot into skull/brain

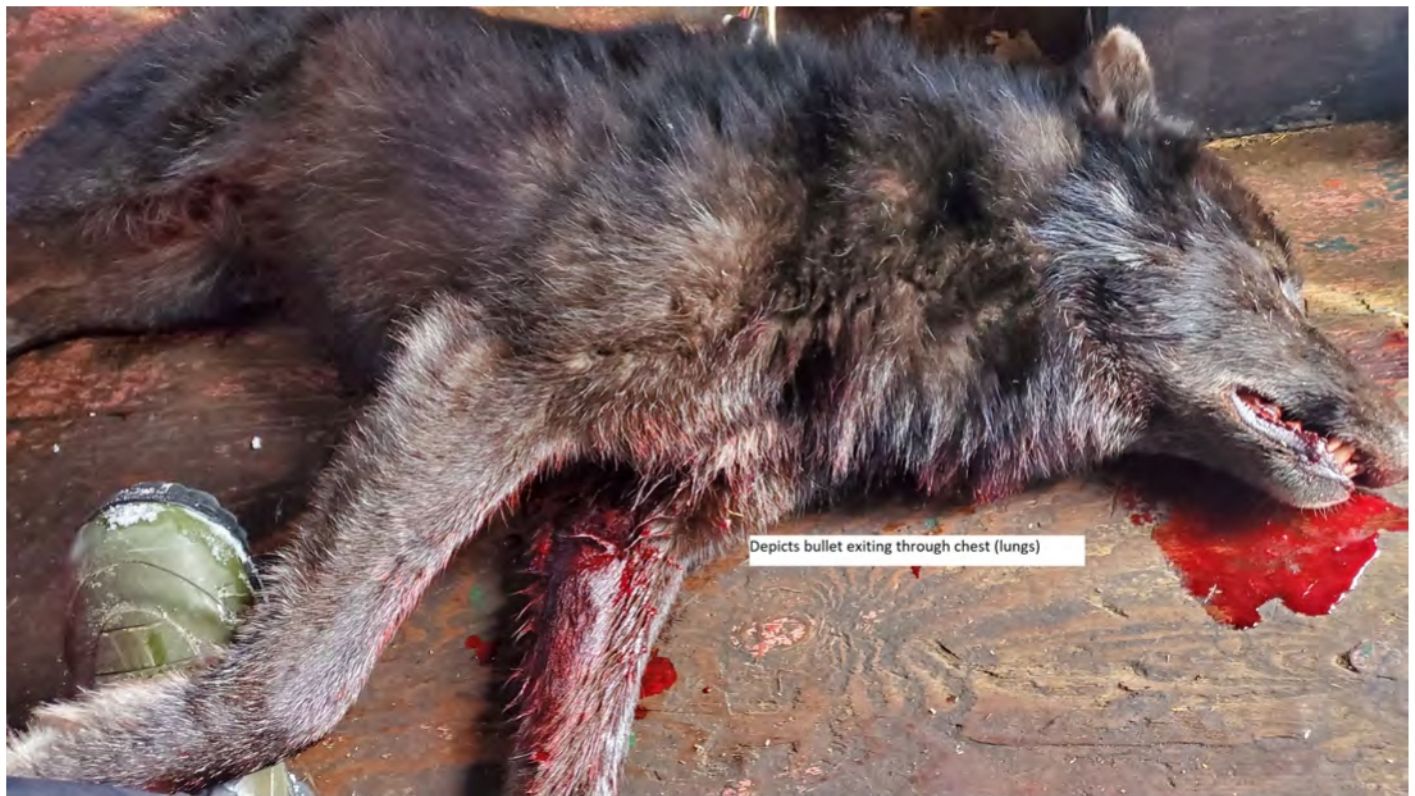





Bullet entry through chest (lung/heart)

Secondary bullet entrance through neck/spine





Additional photo displaying bullet exit(s) through chest





Bullet exit in centre of chest/sternum
after traveling vertically through spine
and chest (lungs) for an instant dispatch



Second bullet exit after follow-up shot through skull/brain

First bullet exit from centre of chest (lungs)

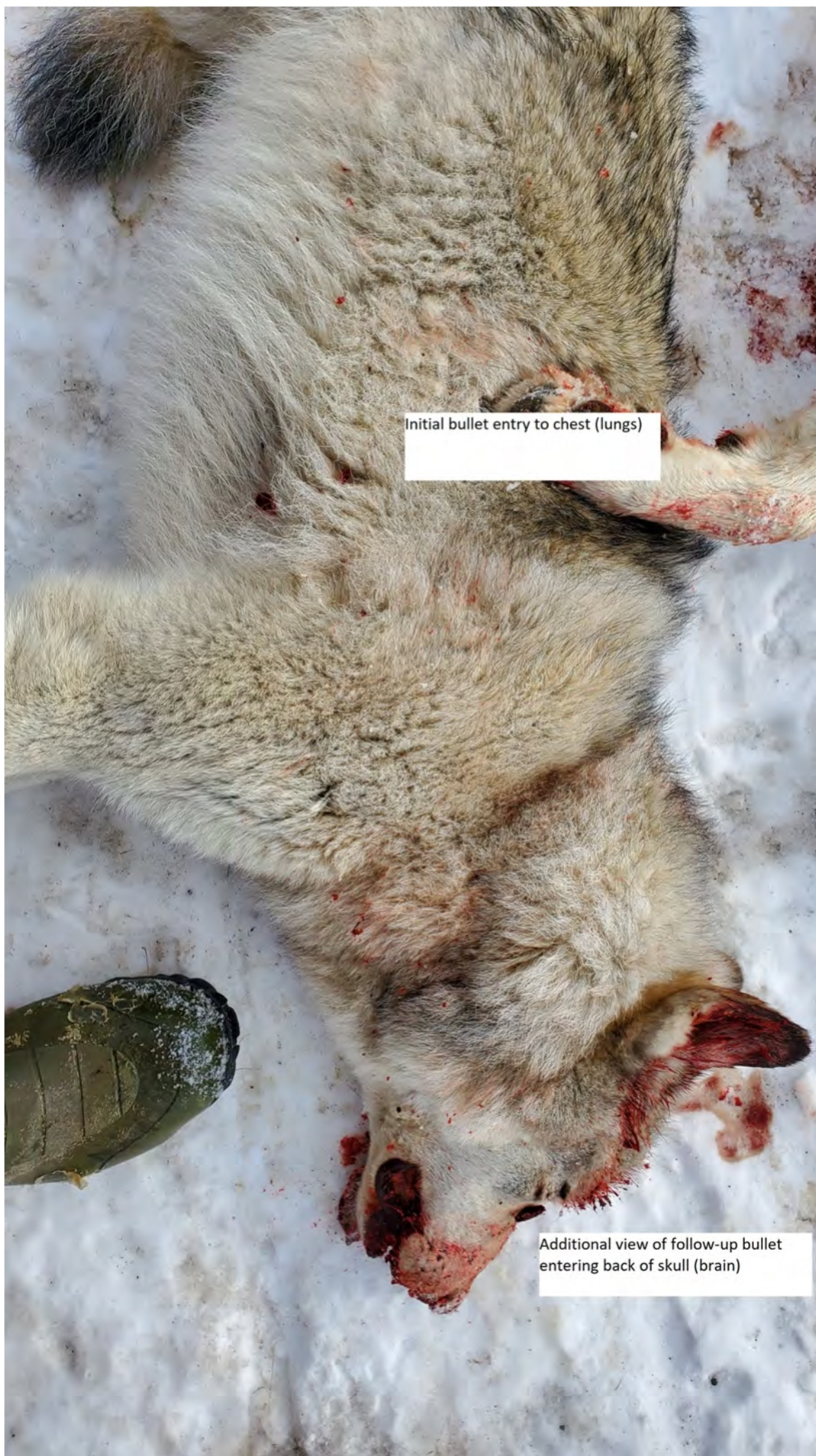

Bullet exit after single shot to skull/brain

Old wound/bite marks to hamstrings from other wolf, presumably



Bullet entrance through back of skull/brain and exit through front of skull

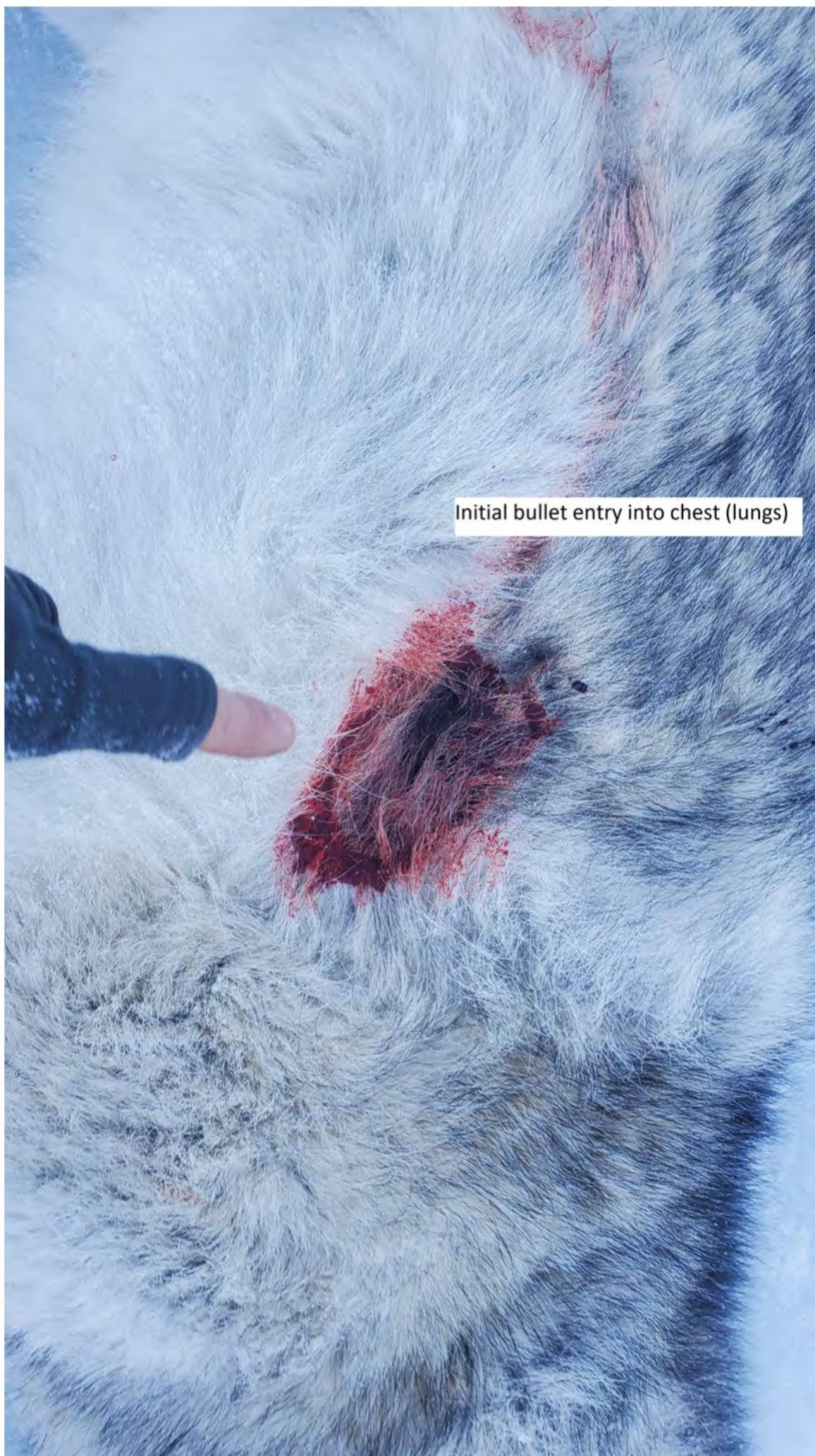

Initial bullet entry to chest (lungs)

Additional view of follow-up bullet entering back of skull (brain)

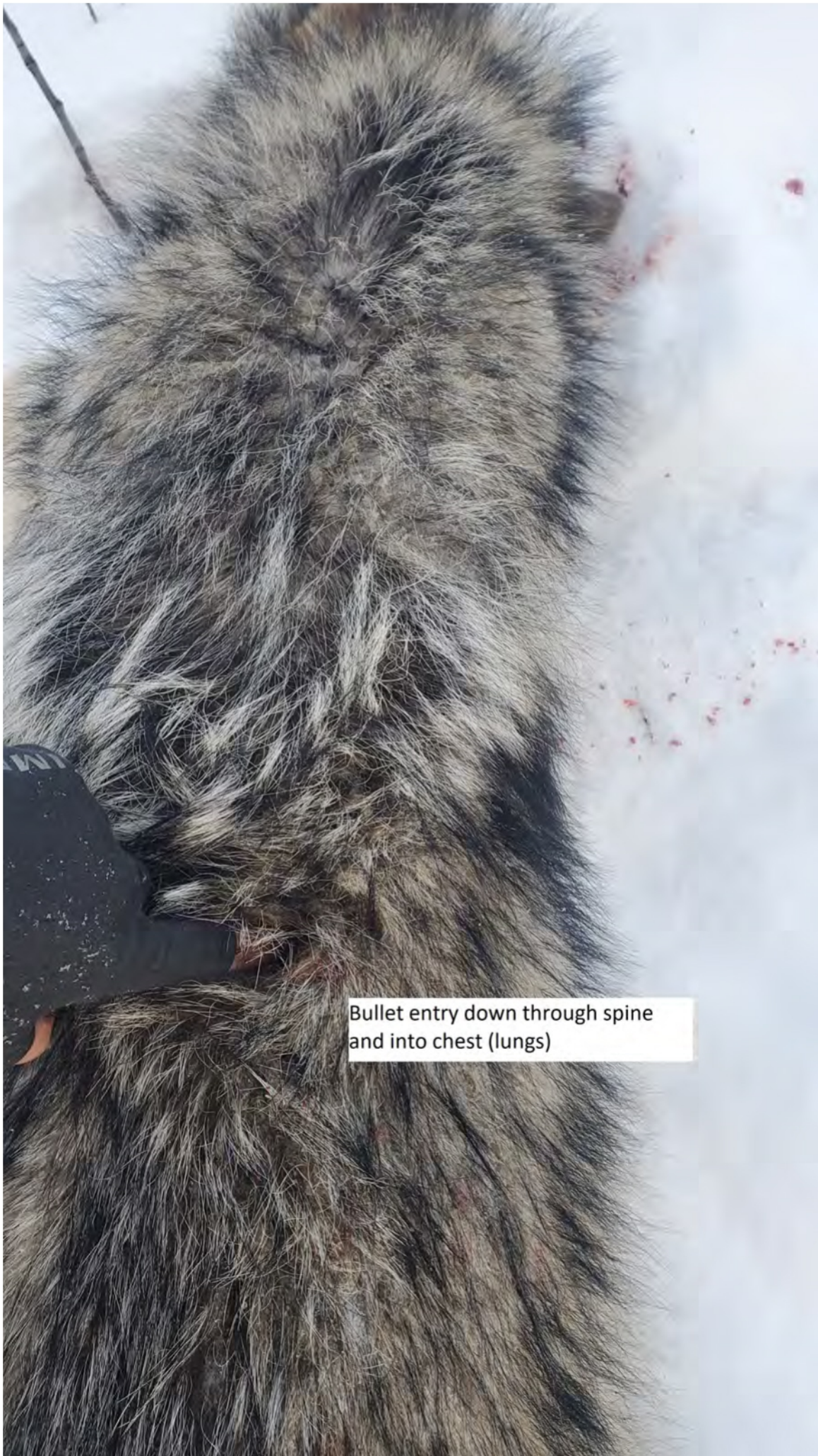

Bullet entry quartering into chest (lungs)



Initial bullet entry into chest (lungs)












Close-up
Bullet entrance through front
of skull (brain)

A photograph of a dead animal, possibly a bear, lying on a light-colored, textured surface. The animal's fur is dark brown and appears matted with blood. There are two distinct bullet wounds. One is located on the lower chest area, and the other is on the neck/spine area. The wounds are surrounded by blood and some tissue damage. The animal's head is visible at the top of the frame, and its body extends downwards.

Secondary bullet into
neck/spine

Initial bullet entrance through
lower chest (heart)









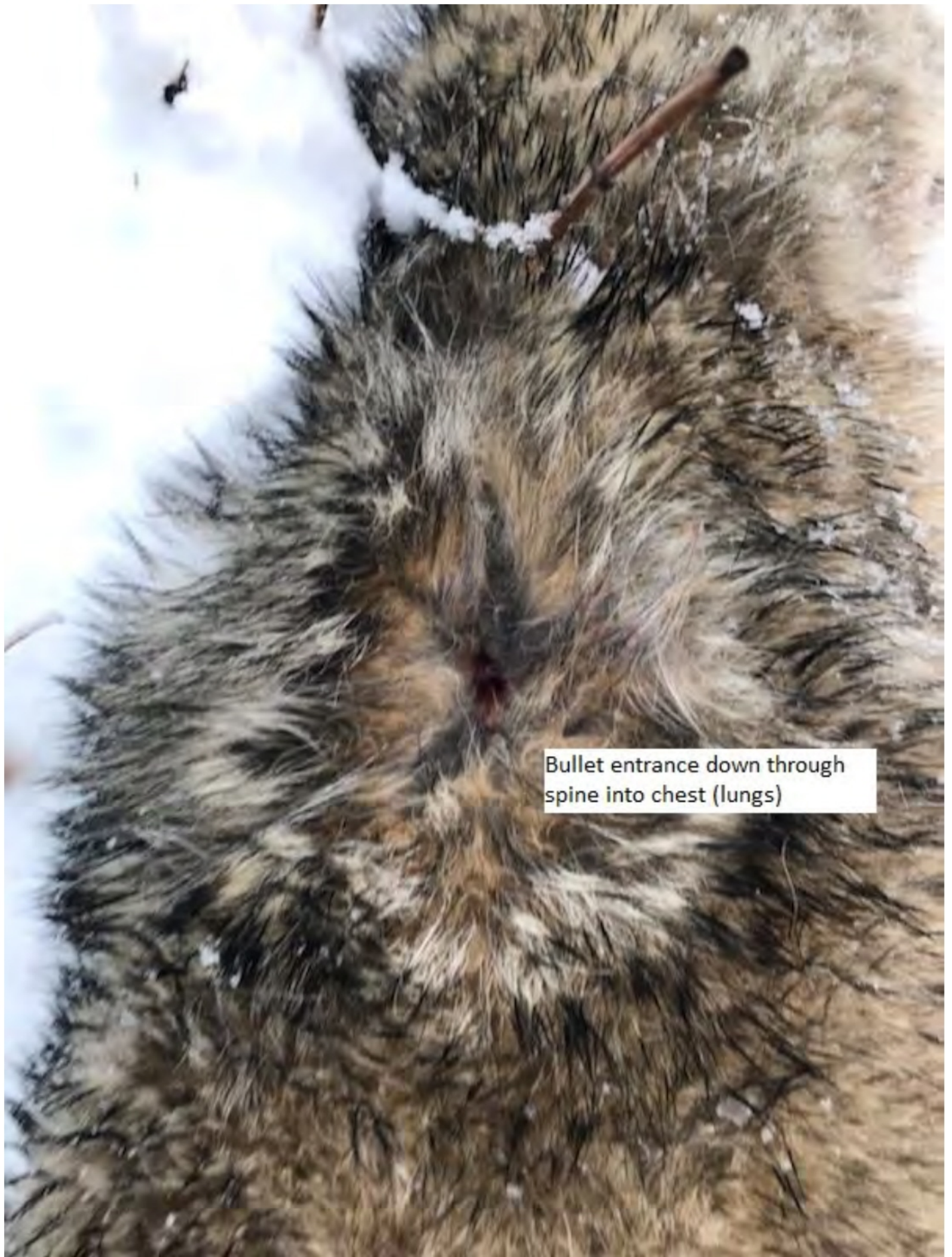Photo depicting instant dispatch
of wolf



Photo depicting instant
dispatch of wolf



Bullet exit after passing through chest (lung/heart) and angling out lower shoulder



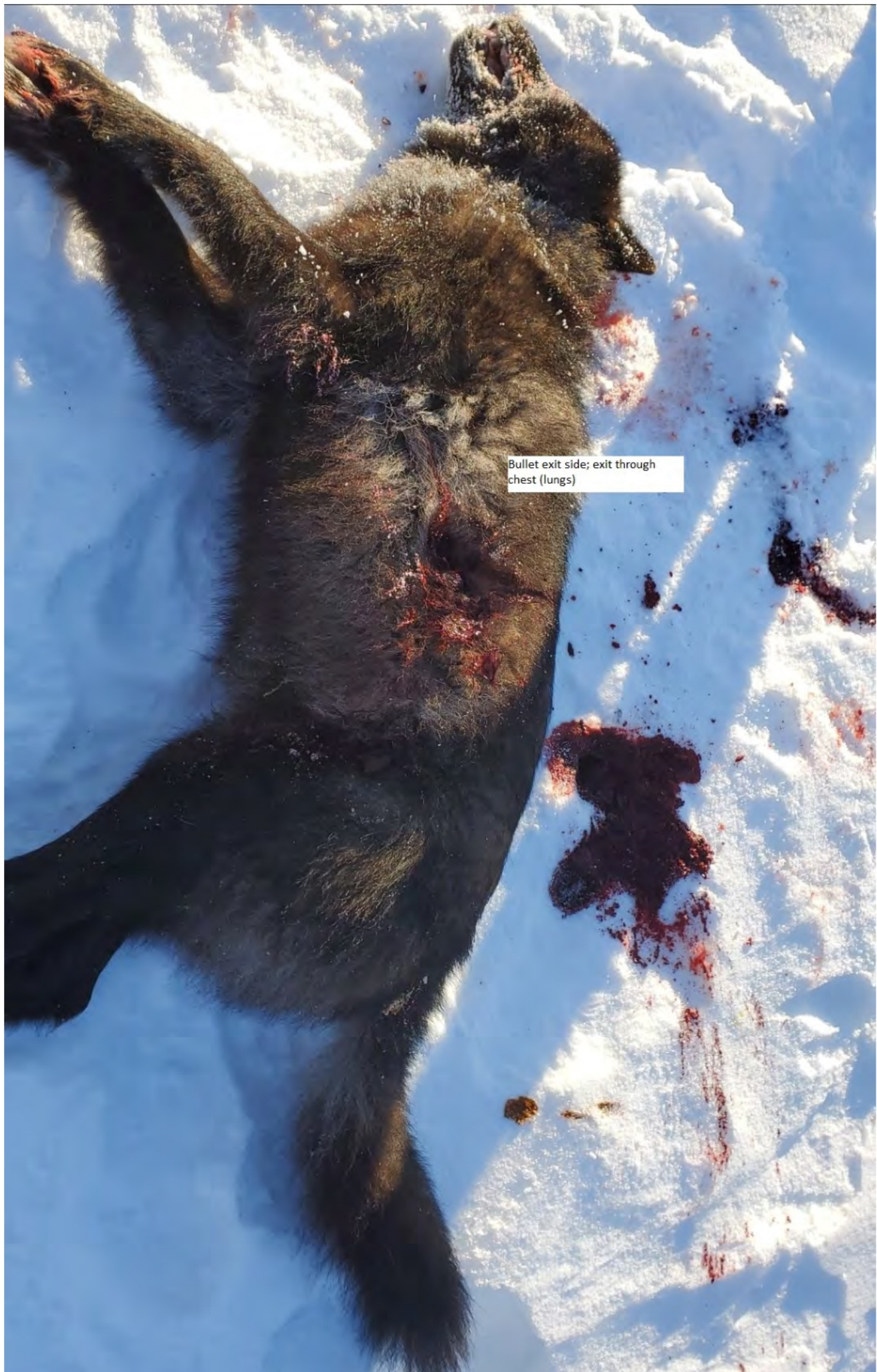Bullet entrance down through spine into chest (lungs)











Bullet exit side; exit through chest (lungs)

